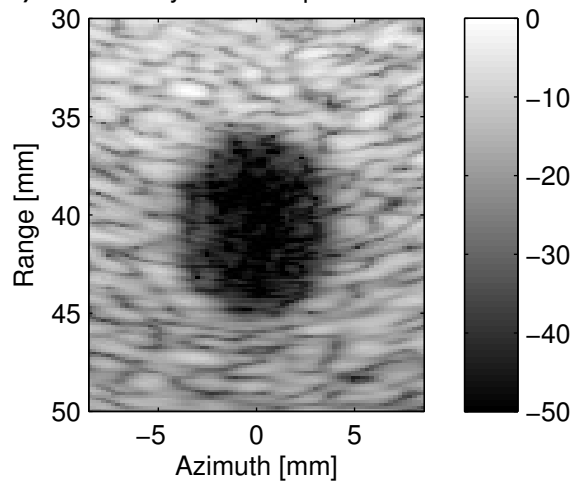



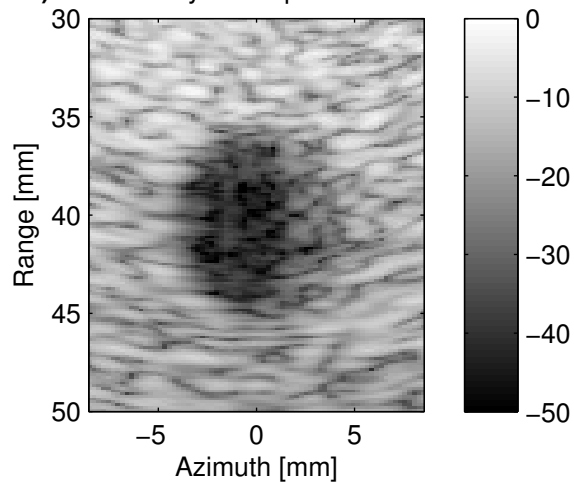
a) Anechoic cyst without phase aberrations



b) Point scatterer without phase aberrations



c) Anechoic cyst with phase aberrations



d) Point scatterer with phase aberrations

